

A comparative study of adrenalin and fluocinolon induced oxidative stress in male wistar rats

Erika Kis¹✉

¹*Babeș-Bolyai University, Faculty of Biology and Geology,
Hungarian Department of Biology and Ecology, Cluj-Napoca, Romania;*
✉ **Corresponding author, E-mail: kiserika2001@yahoo.com.**

*Article history: Received 12 August 2020; Revised 2 November 2020;
Accepted 15 November 2020; Available online 20 December 2020.*

Abstract. Hormone secretion by the hypothalamic-pituitary-adrenocortical (HPA) axis is modulated by multiple factors which include the circadian rhythm, various types of stressors and glucocorticoids. Treatment with synthetic glucocorticoids as e.g. dexamethasone or dermocorticosteroids and repeated immobilization stress, decreases the total body weight gain of animals by disturbing the HPA axis function and accelerating the catabolism of the organism. Synthetic glucocorticoids are widely used as anti-inflammatory and anti-allergic drugs. Nevertheless, their administration may cause side effects in the normal functioning of several organs. Starting from the above findings and from the important physiological roles of the glucocorticoids in the metabolism, we investigated the reactions of the adrenal and thymus, the evolution of the body and organ weight and the level of the free radicals after adrenaline- and fluocinolon stress. In this study, we used electron paramagnetic resonance spectroscopy for the direct detection of free radical content in the organs of stressed Wistar rats. We followed the changes of the blood glucose level, body weight, structural modification and whole redox state of the rats during adrenaline and Fluocinolon-acetonid N treatment, as endogenous and exogenous sources of elevated glucocorticoid levels. We found a relationship between changes of the redox state and modified homeostasis of the organism, as an effect of elevated glucocorticoid levels. The oxidative stress induced by adrenalin treatment seemed to be an inducer rather than the result of the tissue damage.

Keywords: stress, thymus, adrenal, free radicals.

Introduction

Synthetic glucocorticoids are widely used as anti-inflammatory and anti-allergic drugs (Kis and Crăciun 2006, Adcock and Mumby 2017, Barnes 2017). Nevertheless, their administration may cause side effects in the normal

functioning of several organs. Organisms survive by maintaining equilibrium with their environment. The stress system is critical to this homeostasis. Glucocorticoids modulate the stress response at a molecular level by altering gene expression, transcription, and translation, among other pathways. Glucocorticoids also modulate the growth, reproductive and thyroid axes (Kis and Crăciun 2006). It is well known that glucocorticoids are stress hormones produced in response to many common stressors, such as immobilization, cold and physical overload, and are essential for general adaptive responses. Excessive glucocorticoid secretion or treatment, on the other hand, has been reported to have deleterious effects on the organism - it can induce tissue injury and even cell death (Crăciun *et al.*, 1997, Crăciun *et al.*, 1998). Madar and co-workers (1993) have studied the effect of excessive glucocorticoid levels generated through repeated formaldehyde stress or Fluocinolon acetonid-N (FC) treatment in rats. Formaldehyde was used as an endogenous glucocorticoid inducer, while FC was an exogenous source of the hormone. Both formaldehyde- and FC-treated groups showed significant metabolic disorders. The exact mechanism of glucocorticoid-induced cell death is unknown, but several reports indicate that the glucocorticoid-mediated generation of reactive oxygen species (ROS) occurs with the concomitant increase of calcium influx and morphological degeneration and apoptosis of different cells (Landfield and Eldridge 1994, Liu *et al.*, 2018, Deng *et al.*, 2019). In recent studies elsewhere we have reported that the short-term and long-term percutaneous applications of halogenated glucocorticosteroids in pregnant rats induced changes of thymus oxidative status of dams and newborn animals (Kis and Andras 2017). In immobilization-stressed rats, where glucocorticoid levels were slightly elevated, a marked increase in lipid peroxidation was measured in addition to the inhibition of total body weight gain, showing the involvement of ROS (Yan *et al.*, 2000).

Despite numerous investigations, the involvement of free radicals in glucocorticoid-induced alteration is not fully elucidated. In our experiments we followed the changes of body- and some gland weight, the level of free radicals in these glands and the histological aspects of the rat thymus and adrenals during adrenalin (ADR) and Fluocinolon (FC) treatment. We used adrenalin and Fluocinolon-acetonid-N oitment, as endogenous and exogenous sources of elevated glucocorticoid levels. Therefore, the main objective of this study is to determine correlations between glucocorticoid excess and free radical parameters induced by FC and ADR treatment.

Materials and methods

The experiments were carried out in male Wistar rats. The animals were kept under standardized bioclimatic conditions and fed on common rat chow, with water *ad libitum*.

Commercial Fluocinolon-acetonid-N ointment containing 25 mg Fluocinolon-acetonid-N/100 g excipient, was applied topically to the skin at 2 cm², for five consecutive days, by smearing 50 mg ointment/100 g bw. on the inguinal region, the daily dose of ointment being equal to 12,5 µg/100 g bw. The ADR-treated animals were injected subcutaneously with 0.125 ml of adrenalin (0.1%) solution. The animals were divided into the following groups:

C-control group, untreated animals.

FC-Fluocinolon-acetonid-N-treated animals

ADR- adrenalin-treated group

After 16 hours of fasting and 24 hours following the cessation of treatments, the treated animals together with controls were sacrificed by exsanguination.

Blood samples were obtained from all rats at the end of the experiment and blood glucose levels were measured with Spekol spectrophotometer. The value of the glucose was expressed in mg glucose per 100 ml blood.

The body, adrenals and thymus weights of male rats were measured with an accuracy of 0.00001 g immediately after excision. Before the tissue withered away, they were placed in frozen liquid nitrogen to examine the total level of free radical of the glands. The free radical concentration in frozen samples was measured by electron spin resonance (ESR) spectroscopy. Reduced glutathione (GSH) and glutathione disulfide (GSSG) ratio was determined by tissue homogenization (Kis 2012, Schafer and Buettner 2001, Tietze 1969). The experimental data were evaluated using the computer program statistica 99. The mass, ESR signal intensity, antioxidant capacity and GSH/GSSG ratio values showed a non-parametric distribution (Mann-Whitney U test), so the significance levels were determined by parametric t-test. A $p < 0.05$ was considered statistically significant.

The thymus and adrenal gland were fixed in Bouin liquid and afterwards processed in view of being embedded in paraffin. The fragments were sectioned at the Reichart microtome with a thickness of 7 µ. The staining of glands was carried out by the method of Hurduc and co-workers (Mureşan *et al.*, 1974). The histological preparations obtained were examined on the IORC₄ optical microscopy.

Results

The effects of adrenalin and Fluocinolol-acetonid-N treatments upon the blood glucose level

In both treated groups we observed a significant increase of blood glucose level (Fig.1), which means that the blood level of the glucocorticoids increases, on the one hand due to the treatment with exogenous glucocorticoid, and on the other hand, due to adrenalin stress. We used glicemy as an indirect indicator for the action of glucocorticoids. We assumed that the high blood glucose level in our experimental protocol was caused by high levels of glucocorticoids.

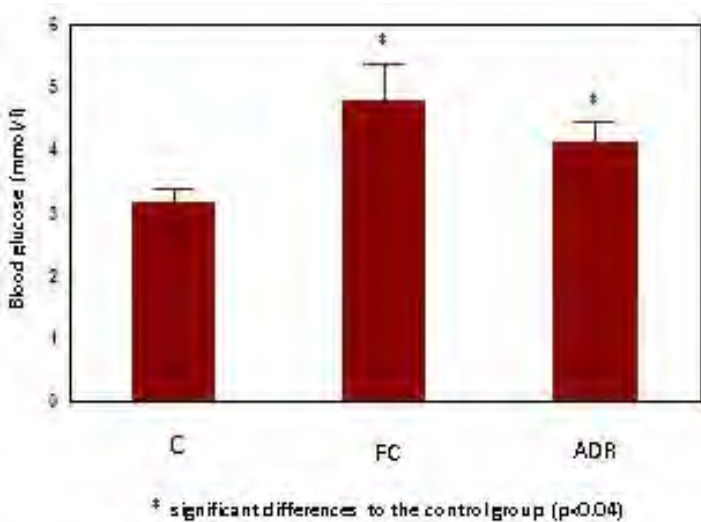


Figure 1. Blood glucose level in controls and treated animals with FC and ADR

The effects of adrenalin and Fluocinolol-acetonid-N treatments upon the body weight

The results presented in fig. 2 show that in our experiment fc treatment and adr stress caused a progressive inhibition of total body weight gain of animals compared to the controls.

STRESS EFFECT IN MALE WISTAR RATS

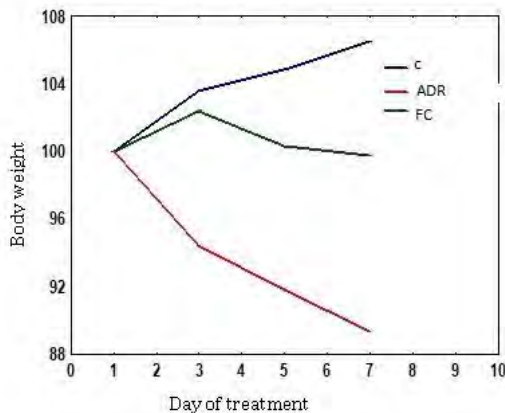


Figure 2. Evolution of the body weight under adrenalin (ADR) and Fluocinolon (FC) treatment in comparison with control.

The Fluocinolon-acetonid-N treatment caused a significant weight loss in contrast with the control group (Fig. 3). However, a significant weight loss in FC group was observed as compared to the ADR treated animals. Body weight loss in ADR-treated group was lower than in the FC-treated one, showing that ADR induces a milder stress than the direct cortisol treatment.

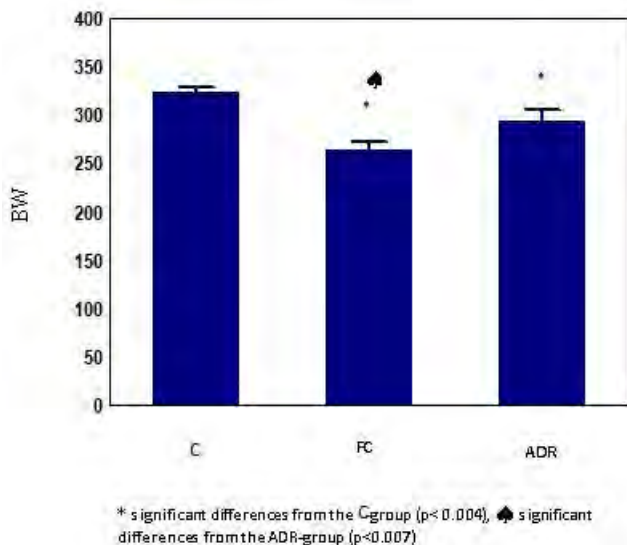


Figure 3. The body weight in the last day of the treatments in control and treated groups

The effects of adrenalin and Fluocinolon-acetonid-N treatments upon the adrenal gland

The relative adrenal weight (Fig. 4.) decreased in FC group comparative with the control and ADR group. In the ADR group we observed a slight increase of the gland weight. These findings are in compliance with our histological results. The free radical concentration increased considerable in the FC group and decreased in the ADR group compared to controls (Fig. 5).

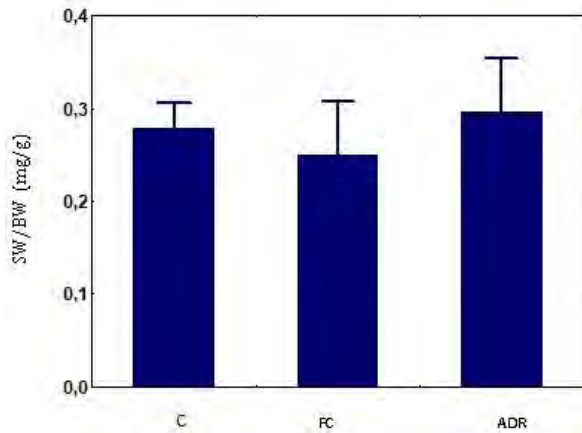


Figure 4. The relative weight of the adrenal gland (SW-suprarenal weight, BW-body weight) in control and treated groups

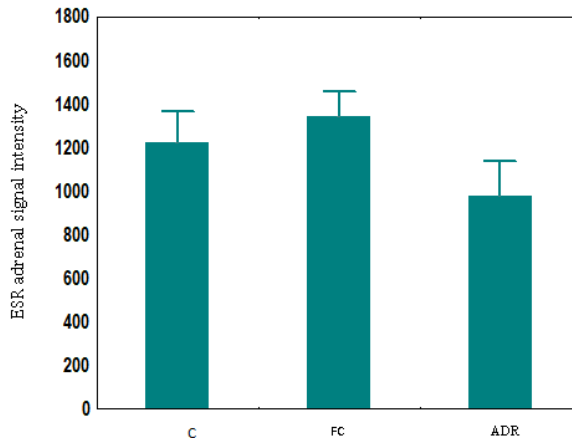


Figure 5. Steady state free radical concentration in adrenal gland under FC and ADR treatment in comparison to the control

Modification of the gland weight and the free radical concentration are in concordance with the results of the microscopical examination (Fig. 6 a). The suprarenal gland of animals treated with Fluocinolon is atrophied in the cortical part (Fig. 6 b), whereas in animals treated with adrenalin we observed the hypertrophy of the gland in the cortical zone (Fig. 6 c). In the FC treated group we observed a hypertrophy of the medullary part of the gland, suggesting a stressful effect of the glucocorticoid treatment.

Spongyocytes and balonated cortical cells appeared in this group. In the medullary part we observed congested capillary. In the ADR group we observed dark zone in the cortical part of the gland, suggesting an increased synthetic activity of the cells.

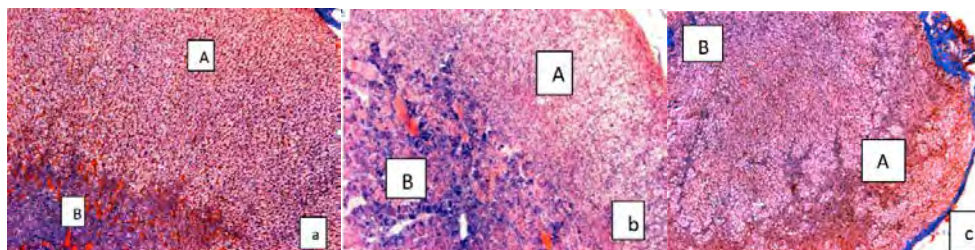


Figure 6. Histological aspect of adrenal gland: a) normal aspect, b) hypertrophy of medullary part (B) and atrophy of the cortical zone (A) in FC group, c) hypertrophy of cortical zone (A) and atrophy of medullary part (B) in ADR group(x 20).

The effects of adrenalin and Fluocinolon-acetonid-N treatments upon the thymus

The relative thymus weight was significantly reduced in FC group (Fig. 7) During the adrenaline treatment we observed a slight decrease of the thymus weight. The steady state free radical concentration increased in FC group in comparison with the control group. These finding are in concordance with the loss of weight in FC group. In ADR group we observed a significant decrease of the steady state free radical concentration in comparison with FC group.

The ratio of GSH/GSSG increased significantly in ADR group as compared with controls (Fig. 8). Modification of steady state free radicals and the GSH/GSSG ratios indicated changes in the redox state of organs of treated animals (Fig. 9).

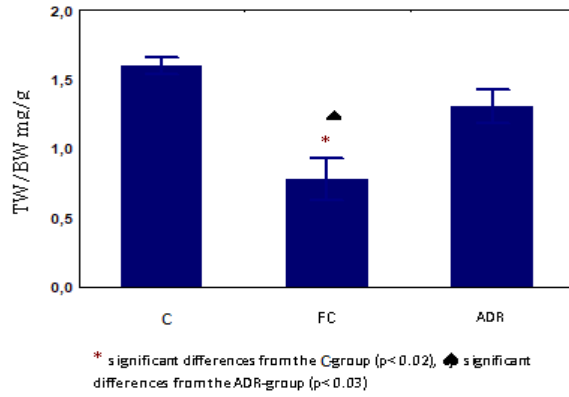


Figure 7. The relative weight of the thymus in control and treated groups

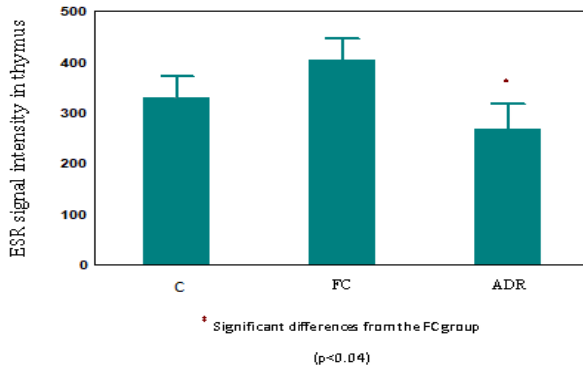


Figure 8. Steady state free radical concentration in the thymus, in control and treated groups

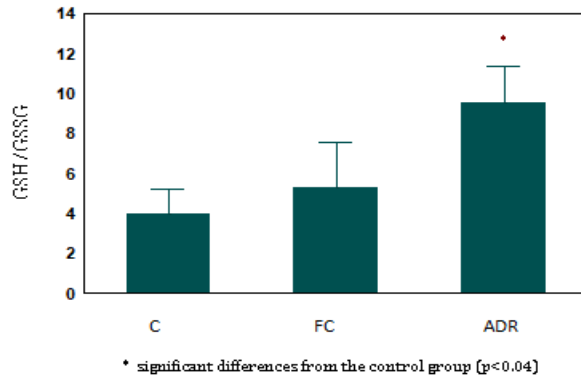


Figure 9. GSH/GSSG in thymus in control and treated groups

The microscopic studies confirm the weight loss of the thymus (Fig. 10 a). Fluocinolon treatment caused the atrophy of the thymus (Fig. 10 b), while in the animals treated with adrenalin the thymus structure hardly differed from the control group (Fig. 10 c). In the FC treated group (Fig. 10 b) we observed a significant rarefication of the cortical and medullary zone of thymic lobule. This means that FC induced an acceleration of thymocytes apoptosis.

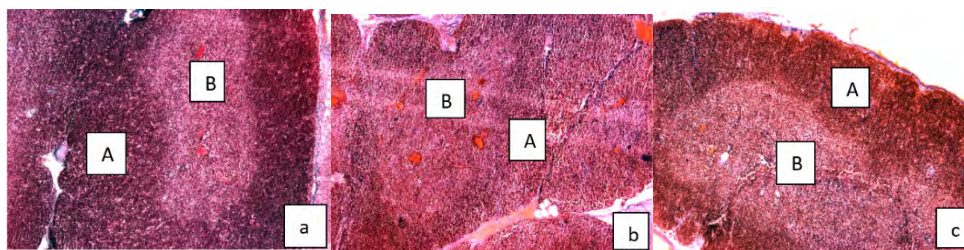


Figure 10. Histological aspects of thymus a) normal structure, A-cortical part of the thymic lobule, B -medullary part of the lobule b) relatively normal aspect of thymus in ADR group, c) moderately altered in FC group (x10)

Discussion

The most frequently studied effect of glucocorticoid application was the impact on blood sugar level. The excess of glucocorticoids increases in liver the storage of glycogen, obstructs the movement of glicogen in the blood and stimulates the glucogenesis (Ivy *et al.*, 2016, Waldron *et al.*, 2013). Glucocorticoids inhibit the uptake and usage of sugar in the muscle and adipose tissues (Gounarides *et al.*, 2008, Lundgren *et al.*, 2004)]. In a long term glucocorticoid application, initial insuline resistance appears at the final stage of diabetes mellitus (Madar *et al.*, 1993). On the basis of these data from the literature corroborated with our experimental data we can conclude that the high level of glucose from the blood is an indicator of the increased level of glucocorticoids. Excessive glucocorticoid level can also activate the HPA axis (Paragliola *et al.*, 2017). Adrenalin has been shown to stimulate both glucose metabolism and H₂O₂ release by macrophages (Costa Rosa *et al.*, 1995).

Excessive exogen glucocorticoid administration inhibits somatotrophic hormone release (Kis *et al.*, 2001) and can cause significant decrease of total body weight [Crăciun *et al.*, 1998, Crăciun *et al.*, 1997, Kis and Crăciun 2006, Orzechowski *et al.*, 2000a). In our work, we used FC ointment as a synthetic source of glucocorticoids and ADR as an endogenous inducer of glucocorticoid production in rats. The observed changes in total body mass and in some organs

weight modification indicate that both exogenously added and ADR-induced glucocorticoid increase induced the activation of catabolic pathways in the rat organism, only ADR turned out to be a milder stressor than FC. A similar situation has been described, where formaldehyde treatment resulted to be less stressful to rats than FC (Madar *et al.*, 1993).

Stress causes disturbances in the homeostasis of the organism, which may lead to tissue injury. Glucocorticoids are widely used as anti-inflammatory drugs because of their immunosuppressive activity (Daley-Yates 2015). Yet, the presence of high glucocorticoid levels can cause secondary side effects such as tissue damage and cell death (Deng *et al.*, 2019, Mann *et al.*, 2000, Nittoh *et al.*, 1998, Orzechowski *et al.*, 2000b, Sapolsky *et al.*, 1999, 2000).

We have detected a severe degeneration of the thymus in response to FC treatment and adrenal atrophy, although Madar and co-workers (1993) was able to detect adrenal atrophy induced by a two-fold higher dose of FC. To find out whether glucocorticoid-induced tissue damage was related to oxidative stress, we have measured several redox parameters such as steady state level of free radicals and the ratio of GSH/GSSG.

Orzechowski and co-workers (Orzechowski *et al.*, 2000a) described a strong oxidative stress in old and young rats induced by dexamethasone treatment, which was manifested by a significant decrease of blood GSH levels and spleen atrophy. Mild oxidative stress was detected in rats treated with two times lower dose of dexamethasone, as measured by enhanced glutathione peroxidase and catalase activities, as well as reduced thiobarbituric acid reactive substance content in thymus and spleen (Pereira *et al.*, 1998, 1999). In every case, oxidative stress was associated with organ atrophy indicating that tissue degeneration may be related to changes in the redox state of the organs. Glutamine oxidation is stimulated by adrenaline, thus providing increased substrate (malate) for NADP (+)-dependent 'malic' enzyme (Madar *et al.*, 1993, Pereira *et al.*, 1995). In our experiments, ADR treatment resulted in mild thymus atrophy, which was associated with drastically increased GSH/GSSG ratio. Free radical concentration in the organ was not elevated suggesting that the glutathione antioxidant machinery has been induced by pro-oxidants and was able to prevent the development of oxidative stress in the tissue. FC, on the other hand, induced severe thymus atrophy followed by high free radical concentrations. Interestingly, GSH/GSSG ratio remained normal, suggesting that the antioxidant machinery was not induced anymore and was unable to prevent oxidative injury. The changes in the antioxidant defense system of the thymus may be an explanation why this organ is more susceptible to FC treatment. An intensive glucocorticoid treatment or chronic stress can cause changes in the redox state of the lymphoid organs, modifying the activity of antioxidant enzymes and can influence the antibacterial and antiviral defense (Gavan *et al.*, 1997, Seiji *et al.*, 1997, Pereira *et al.*, 1999).

The fact that the antioxidant system of thymus was induced before the atrophy developed suggests that pro-oxidants are generated at a very early stage of tissue degeneration. By the time organ atrophy fully developed, the induction of GSH synthesis ceased and oxidative stress evolved in thymus and adrenal gland. These observations suggest that oxidative species are present at the very beginning of glucocorticoid-induced tissue injury and may participate in the process of organ degeneration. It will be interesting to investigate whether co-administration of glucocorticoids to rats with different antioxidants could be useful in preventing organ atrophy.

Conclusions

In summary, we can conclude:

Glucocorticoids can induce oxidative stress and lead to tissue injury even at relatively low doses.

Milder and more severe organ atrophies were observed in the thymus and adrenal of ADR and FC treated rats, which was associated with oxidative stress measured in these tissues.

The response to elevated glucocorticoid levels was tissue-dependent, thymus being the most susceptible to injury from among the studied organs.

The oxidative stress takes place in the organs from the very beginning of the atrophic process, suggesting that it is not merely a result but rather an active participant of degeneration.

References

- Adcock, I.M., & Mumby, S. (2017). Glucocorticoids, *Handb. Exp. Pharmacol.*, 237: 171-196. doi:10.1007/164_2016_98.
- Barnes, P.J. (2017). Glucocorticosteroids, *Handb. Exp. Pharmacol.*, 237: 93-115. doi: 10.1007/164_2016_62.
- Costa Rosa, L. F., Curi, R., Murphy, C., & Newsholme, P. (1995). Effect of adrenalin and phorbol myristate acetate or bacterial lipopolysaccharide on stimulation of pathways of macrophage glucose, glutamine and O₂ metabolism. Evidence for cyclic AMP-dependent protein kinase mediated inhibition of glucose-6-phosphate dehydrogenase and activation of NADP⁺-dependent 'malic' enzyme, *Biochem. J.*, 310, 709-714.
- Crăciun, C., Madar, I., Tarba, C., Frățilă, S., Ardelean, A., Crăciun, V., & Ilyes, I. (1998). Correlation between ultrastructural thymus modification, thymolysis, thymus and blood-serum lipids in response to epicutaneously applied dexamethasone in pubertal rats, In: *Current Problems in Cellular and Molecular Biology*, Crăciun, C., Ardelean, A., (eds.), Risoprint, pp. 218-235.

- Crăciun, C., Ardelean, A., Madar, I., Tarba, C., Șildan, N., Crăciun, V., & Fărcaș, T. (1997). Ultrastructural studies of the secondary effects induced at the level of thymus by topical application of Fluocinolon-acetonid-N in prepubertal rats, In: *Current Problems and Techniques in Cellular and Molecular Biology*, Crăciun, C., Ardelean, A. (eds.), Mirton, pp.176-186.
- Daley-Yates, P.T. (2015). Inhaled corticosteroids: potency, dose equivalence and therapeutic index, *Br. J. Clin. Pharmacol.*, 80(3): 372-380.
- Deng, S., Dai, G., Chen, S., Nie, Z., Zhou, J., Fang, H., & Peng, H. (2019). Dexamethasone induces osteoblast apoptosis through ROS-PI3K/AKT/GSK3 β signaling pathway, *Biomed. Pharmacother.*, 110, 602-608.
- Gavan, N., Popa, R., Orasan, R., & Maibach, H. (1997). Effect of percutaneous absorption of fluocinolon acetonide on the activity of superoxide dismutase and total antioxidant status in patients with psoriasis, *Skin Pharmacol.*, 10, 178-82.
- Gounarides, J.S., Korach-André, M., Killary, K., Argentieri, G., Turner, O., & Laurent, D. (2008). Effect of dexamethasone on glucose tolerance and fat metabolism in a diet-induced obesity mouse model, *Endocrinol.*, 149 (2), 758-766.
- Ivy, J.R., Oosthuyzen, W., Peltz, T.S., Howarth, A.R., Hunter, R.W., Dhaun, N., Al-Dujaili, E.A.S., Webb, D.J., Dear, J.W., Flatman, P., & Bailey, A.M. (2016). Glucocorticoids induce nondipping blood pressure by activating the thiazide-sensitive cotransporter, *Hypertension*, 67, 1029-1037.
- Kis, E. (2012). Glucocorticoid excess and fetal development in white Wistar rats. *Annals of Romanian Society for Cell Biology*, 17 (2), 82-85
- Kis, E., & András, P. (2017). Has the Fluocinolon-acetonid N ointment any effect on the kidneys and the thyroid gland structure and function? *Studia UBB Biologia*, 62(2), 41-52..
- Kis, E., & Crăciun, C. (2006). Efecte secundare ale unor glucocorticoizi topici, *Ed. Risoprint*, Cluj-Napoca.
- Kis, E., Crăciun, C., Pașca, C., Sandu, V. D., Crăciun, V., & Madar, I. (2001). Comparative studies of the ultrastructure of somatotrope, gonadotrope and corticotrope cells in mature rats treated with topical dermocorticoids, *Studia UBB Biologia*, 46(1), 99-110.
- Landfield, P.W., & Eldridge I.C. (1994). The glucocorticoid hypothesis of age-related hippocampal neurodegeneration: role of dysregulated neuronal calcium, *Ann. N. Y. Acad. Sci.*, 746, 308-321.
- Liu, W., Zhao, Z., Na, Y., Meng, C., Wang, J., & Bai, R. (2018). Dexamethasone-induced production of reactive oxygen species promotes apoptosis via endoplasmic reticulum stress and autophagy in MC3T3-E1 cells, *Internat. J. Molec. Medicin*, 41(4), 2028-2036.
- Lundgren, M., Burén, J., Ruge, T., Myrnäs, T., & Eriksson, J.W. (2004). glucocorticoids downregulate glucose uptake capacity and insulin-signaling proteins in omental but not subcutaneous human adipocytes, *J. Clin. Endocrinol. Metab.*, 89 (6), 2989-2999.
- Madar, I., Șildan, N., & Frecuș, G. (1993). Studiul comparativ al efectului stresului și tratamentului cu fluocinolon-acetonid asupra unor parametri endocrino-metabolici la șobolani Wistar tineri, *Științe și cercetări biologice, Seria Biol. Anim.*, t. 45(1), 53-59.

- Mann, C.L., Hughes, F.M., & Cidlowski, J.A. (2000). Delineation of the signalling pathway involved in glucocorticoid-induced and spontaneous apoptosis of rat thymocytes, *Endocrinol.*, 141:528-538.
- Mureșan, E., Gaboreanu, M., Bogdan, A.T., & Baba, A.I. (1974). Tehnici de histologie normală și patologică, *Ed. Ceres*, București, 482pp.
- Nittoh, T., Fujimoti, H., Kozumi, Y., Ishihara, K., Mue, S., & Ohuchi, K. (1998). Effects of glucocorticoids on apoptosis of infiltrated eosinophils and neutrophils in rats, *Euro. J. Pharmacol.*, 354, 73-81.
- Orzechowski, A.J., Grizard, M., Jank, B., Gajkowska, M., Lokociejewska, M., & Godlewskia, M. (2000a). Dexamethasone-mediated regulation of death and differentiation of muscle cells. Is hydrogen peroxide involved in the process? *Reprod. Nutr. Develop.*, 42,197-216.
- Orzechowski, A.P., Ostaszewski, J., Wilczak, M., Jank, B., Balasinska, P., & Wareski, J. F. (2000b). Rats with a glucocorticoid-induced catabolic state, show symptoms of oxidative stress and spleen atrophy: the effect of age and recovery, *J. Vet. Med.*, 49, 256-263.
- Paragliola, R.M., Papi, G., Pontecorvi, A., & Corsello, S.M. (2017). Treatment with synthetic glucocorticoids and the hypothalamus-pituitary-adrenal axis. *Internat. J. Mol. Sci.*, 18(10), 2201.
- Pereira, B., Costa-Rosa, L.F.B.P., Bechara, E.J.H., Newsholme, P., & Curi, R. (1998). Changes in TBARs content and superoxid dismutase, catalase and glutathione peroxidase activities in the lymphoid organs and skeletal muscles of adrenodemedullated rats, *Braz. J. Med. Biol. Res.*, 31, 827-833.
- Pereira, B., Costa Rica, L.F.B.P., Safi, D.A., Bechara, E.J.H., & Curi, R. (1995). Hormonal regulation of superoxid dismutase, catalase, and glutathione peroxidase activities in rat macrophages, *Biochem. Pharmacol.*, 50 (12): 2093-2098.
- Pereira, B., Bechara, E.J.H., Mendoca, J.R., & Curi, R., (1999). Superoxid dismutase, catalase and glutathione peroxidase activities in teh lymphoid organs and skeletal muscles of rats treated with dexamethasone, *Cell Biochem., Funct.*, 17, 15-19.
- Sapolsky, R. M. (1999). Glucocorticoids, stress, and their adverse neurological effects: relevance to aging, *Exper. Gerontol.*, 34, 721-732.
- Sapolsky, R.M., Romero, L.M., & Munck, A.U. (2000). How do glucocorticoids influence Stress Responses? Integraing, Permissive, Supressive, Stimulatory and Preparative Actions, *Endocr. Rev.*, 21(1), 55-89.
- Schafer, Q.F., & Buettner, R.G. (2001). Redox environment of the cell as viewed trough the redox state of the glutathione disulfide/glutathione couple, *Free Radic. Biol. Med.*, 30(11), 1191-1212.
- Seiji, M., Yasuaki, N., Eisuke, F., Sato, K.Y., Masanobu, M., & Masayasu, I. (1997). Cold stress induces thymocyte apoptosis in the rat, *Pathophys.*, 213-219.
- Tietze, F., (1969). Enzymic method for quantitative determination of nanogram amounts of total and oxidized glutathione: Applications to mammalian blood and other tissues, *Ann. Biochem.*, 27, 502-522,1969.

- Waldron, N.H., Jones, C.A., Gan, T.J., Allen, T.K., & Habib, A.S. (2013). Impact of perioperative dexamethasone on postoperative analgesia and side-effects: systematic review and meta-analysis, *Br. J. Anaesth.*, 110, 191-200.
- Yan, H., Arturo, C., Erdal, G., Philip, A., & Mohammed, K. (2000). Anti-stress effects of dehydroepiandrosterone, *Biochem. Pharmacol.*, 59, 753-762.